CASE REPORT

Mucoepidermoid Carcinoma of Lung– A Rare Case with Unusual Presentation

Palak Upadhyay*, Ranjita Bansal, Arpita Jindal***, Ajay Yadav*****

ABSTRACT

Mucoepidermoid carcinoma of the lung (MEC) is a rare entity. We present a case of a 36-year-old non-smoker female who presented with cough, fever and left sided chest pain for the past 6 months. Chest X ray revealed as trapped lung and CT demonstrated a left bronchial mass. On CT guided bronchial biopsy, it was diagnosed as squamous cell carcinoma. Diagnosis of MEC was made on pneumonectomy specimen received. The histological grade affects the progression and survival. Although metastasis is rare but it can occur.

Keywords: Mucoepidermoid, lung, carcinoma, rare

INTRODUCTION

Salivary gland type tumours are the unusual family of the primary neoplasms of the lung, the histology of which recapitulates neoplasm of the salivary gland. In general, primary salivary gland tumour of the lungs are rare[1]. Mucoepidermoid carcinoma is common among these rare salivary gland tumours. It can affect males and females across a broad age range, including children and usually present as an exophytic endobronchial mass. These tumours mostly originate from the sub mucosal glands of the bronchi and clinically patient presents with symptoms of bronchial obstruction such as cough, wheezing or atelectasis[2]. They are comprised of cells showing epidermoid differentiation admixed with mucocytes containing mucin[1]. Based on the World Health Organization (WHO) classification these are further sub classified into low grade and high grade with low grade having a good clinical outcome when completely rejected while mucoepidermoid carcinoma with high grade histology show highly aggressive behaviour. Diagnosis relies on the histopathological examination of the biopsy since the clinical and radiological manifestations are not specific[3]. Epidermal Growth Factor Receptor (EGFR) is frequently over expressed in MEC's. Pulmonary MEC's may harbour at (11;19) translocation with an associated novel fusion oncogene (CRCT1-MAML2)[4].

CASE PRESENTATION

A 36-year-oldfemale, non-smoker presented with cough without expectoration, fever and left sided chest pain for 6 months. CT of the chest showed mildly reduced left lung volume with focal area of collapse consolidation in the posterior segment of left lower lobe and near complete obstruction of the lumen of the left lower lobe as shown in image A of Figure 1. Bronchoscopy was performed which showed a reddish irregular growth in left main bronchus which bled on touching the probe. The patient had pleural effusion. Pleural fluid cytology was not significant. Biopsy reported as non-small cell lung cancer. CT of whole abdomen was done which had no significant abnormality. PET-CT showed soft tissue lesion in left hilar region causing compression of left lower lobe bronchus with segmental collapse of left lower lobe region measuring 18x17mm consistent with primary malignant lesion. There was presence of metabolically active enlarged mediastinal lymphadenopathy. A decision was made to proceed with surgery. The patient underwent left pneumonectomy with excision of hilar lymph nodes. Gross of the lung specimen showed a growth near the hilus measuring 2 cm cut surface of which was grey white. Rest of the lung showed dilated tiny bronchioles filled with granular material. Histopathology showed sheets of cell showing epidermoid differentiation admixed with mucocytes containing intracellular and extracellular mucin as shown in image B of Figure 1. The solid

*Resident Doctor, **Senior Demonstrator, ***Senior Professor
Department of Pathology, SMS Medical College, Jaipur
Corresponding Author
Dr. Ranjita Bansal,
Address- sector 5-ta-11, Jawahar nagar, Jaipur.
Email id- ranjitabansal@gmail.com , Contact no- 8955413263

component was composed of large polygonal squamoid cells with pale eosinophilic cytoplasm, moderate nuclear pleomorphism and hyperchromasia with interspersed cystic spaces containing mucin and group of clear cells interspersed within the tumour nest making the diagnosis of High Grade Mucoepidermoid carcinoma (salivary gland type). Lymphovascular and perineural invasion was seen. Tumour was infiltrating adjacent lung parenchyma and bronchi. None of the lymph nodes showed any evidence of metastasis. The diagnosis was made sure by performing mucicarmine which was positive in cystic spaces surrounded by tumour cells as shown in image C of Figure 1. The tumour cells showed cytoplasmic positivity for mucicarmine. On performing immunohistochemistry EGFR was positive as shown in image D of Figure 1.

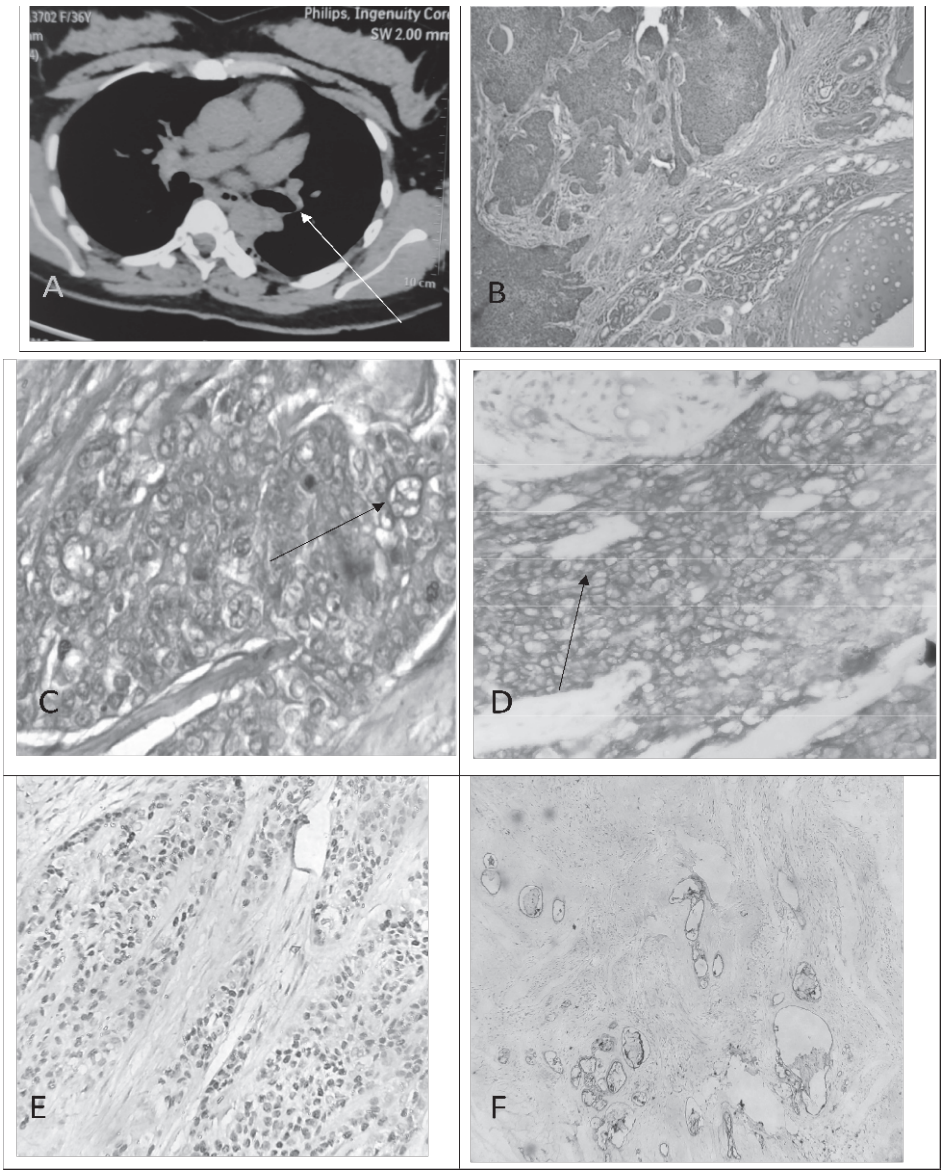

Figure 1: Showing radiological and histopathological images (A) Chest CT of the patient showing patch of mass like consolidation with abrupt cut-off of left lower segmental bronchus (B) Mucoepidermoid carcinoma of lung showing squamous, glandular and cartilaginous component - H &E(100X). (C)Cytoplasm of tumour cells showing positivity for mucicarmine- Mucicarmine stain (400X).(D)IHC staining (400X) membranous positivity of EGFR demonstrated in tumour cells.(E) IHC staining (400X) Nuclear positivity of p63 in the squamous component (F) IHC staining (100X) MUC1 positivity in the glands.

DISCUSSION

Mucoepidermoid carcinoma of the lung is exceedingly rare accounting for 0.1 to 0.5 % of all lung cancers. These tumours may arise from minor salivary glands of tracheobronchial tree presenting as exophytic intraluminal mass on gross and CT, most commonly involving the trachea and /or bronchus. Bronchi show dilatation and are usually filled with mucoid material. Bronchoscopic biopsy and staging plays an important role in diagnosis.

Histologically MEC is comprised of a mixture of cell types including mucin secreting glandular cells, squamous cells, and intermediate cells. The WHO has sub classified MEC into low grade and high grade based on features like cytological atypia, mitotic activity and cellular necrosis. Low grade tumours are composed of three cell types – mucin secreting, squamous and intermediate cells and often show cystic patterns with solid areas. Tumour is land contains both cystic and solid patterns. Cystic components consist of columnar cells with mucin and rare mitosis[3].

High grade mucoepidermoid carcinoma is mainly composed of atypical squamoid and intermediate cells, with frequent mitosis and necrosis accompanied by variable number of mucin secreting cells. Immunohistochemically the tumour cells show positive immunostaining for p63 as shown in image E, MUC1 as shown in image F, p40, pan-cytokeratin, CK7 whereas negative for TTF-1, CK20[3]. Our case was also a high grade MEC with presence of lymphovascular and perineural invasion.

Although metastasis is uncommon it can occur and most commonly seen in regional lymph nodes or other areas of lung tissue[5]. No metastasis was seen in the lymph nodes in our case. Surgical resection remains the standard therapy for patients with pulmonary MEC. Patients with low grade MEC usually have a better prognosis with five-year survival rate approaching 95% but high grade MEC carry a much poorer prognosis.

EGFR may be over expressed in MEC's of salivary gland originas seen in our case. Gene rearrangements have been discovered in pulmonary MECs like t (11;19) translocation with an associated novel fusion oncogene (CRCT1-MAML2). The role of targeted therapy against EGFR or CRCT1-MAML2 fusion protein is yet to be determined.[3]

PURPOSE OF THE STUDY

MEC of lung is a rare malignancy. When a young patient even without history of smoking presents with clinical features and radiological evidence of mass lesion in the lung, the diagnosis of MEC should be made after carefully examining different sections of the tumour. These tumours behave less aggressively than squamous cell carcinoma arising from bronchial epithelium. Our case was diagnosed as high-grade squamous cell carcinoma on biopsy and on pneumonectomy it was confirmed as MEC.

REFERENCES

1. Suster S, Moran CA. Fletcher's Diagnostic Histopathology of Tumour. Tumours of lung and pleura. 4th ed. Philadelphia: Elsevier. 2013;p. 219.
2. Heitmiller RF, Mathisen DJ,Ferry JA, Mark EJ, Grillo HC. Mucoepidermoid lung tumours. Ann Thorac Surg. 1989;47(3):394-9.
3. Limaiem F, Lekkala MR,SharmaS, Cancer, Mucoepidermoid Lung Tumour. 2019 Jan; In: stat Pearls (Treasure Island).1-5.
4. Alsidawi S, Morris JC, Starnes SL, Karim NA, Wikenheiser-Brokamp KA. Mucoepidermoid Carcinoma of the Lung. A case report and Literature Review.Case reports in oncological medicine. 2013 Nov;13:1-5.
5. Thomas D, ModiY, DoraiB, GuronG. A rare case of Lung Carcinoma with Mucoepidermoid Histopathology: A Case Report and Review of the Literature. Ann Clin Lab Sci. March-April 2015;45(2):219-21.